

Case report

Open Access

Monochorionic triamniotic triplet pregnancy with a co-triplet fetus discordant for congenital cystic adenomatoid malformation of the lung

Ahmet Gul*¹, Halil Aslan¹, Altan Cebeci¹, Yavuz Ceylan¹ and Ali Ismet Tekirdag²

Address: ¹Maternal and Fetal Unit, Istanbul Bakirkoy Women and Children Hospital, Istanbul, Turkey and ²Reproductive Medicine Unit, Istanbul Bakirkoy Women and Children Hospital, Istanbul, Turkey

Email: Ahmet Gul* - ahmetgul@ttnet.net.tr; Halil Aslan - halil34aslan@hotmail.com; Altan Cebeci - acebeci@hotmail.com; Yavuz Ceylan - yavuzceylan@yahoo.com; Ali Ismet Tekirdag - aliismetekirdag@hotmail.com

* Corresponding author

Published: 08 April 2005

Received: 25 September 2004

Reproductive Health 2005, **2**:2 doi:10.1186/1742-4755-2-2

Accepted: 08 April 2005

This article is available from: <http://www.reproductive-health-journal.com/content/2/1/2>

© 2005 Gul et al; licensee BioMed Central Ltd.

This is an Open Access article distributed under the terms of the Creative Commons Attribution License (<http://creativecommons.org/licenses/by/2.0>), which permits unrestricted use, distribution, and reproduction in any medium, provided the original work is properly cited.

Abstract

Background: Spontaneous monochorionic triamniotic pregnancy is rare and is at increased risk for pregnancy complications. The presence of an anomalous fetus further complicates the management.

Case presentation: We present a case of monochorionic triamniotic triplet pregnancy diagnosed at 15 weeks of gestation with one fetus having developed a multicystic lung lesion, suggestive of congenital cystic adenomatoid malformation (CCAM). At 24 weeks, the largest cyst measured 10 mm in diameter. We managed the pregnancy conservatively and delivered three live male fetuses with birth weights 1560 g, 1580 g and 1590 g at 35 weeks of gestation. Two newborns were admitted to the neonatal intensive care unit with respiratory distress, the third one died due to sepsis 7 days postpartum. One of the newborns was discharged healthy at 24 days postpartum. The newborn with CCAM developed a pneumothorax on the right side, recovered after treatment, and was discharged after one month. Computerized tomography (CT) of the infant at 3 months demonstrated two cystic lesions in the middle lobe of the right lung measuring 25 mm and 15 mm. A repeat CT of the infant at 6 months showed a 30 mm solitary cystic mass.

Conclusion: Monochorionic triamniotic triplet pregnancy with a co-triplet fetus discordant for CCAM, present rarely and can be managed conservatively. These findings may help in decision making and counselling of parents.

Background

The prevalence of spontaneous triplet pregnancy is about 1 in 7000 deliveries, but with the increasing availability of assisted reproductive technologies, the rate of high-order multiple pregnancies has risen dramatically over the last 20 years [1,2]. Although multiple births have increased

and most of the reported monochorionic triplet pregnancies have been conceived by in-vitro-fertilisation, the monochorionic triplet pregnancy is rare, and is estimated to be approximately 1 in 100,000 births [3,4].

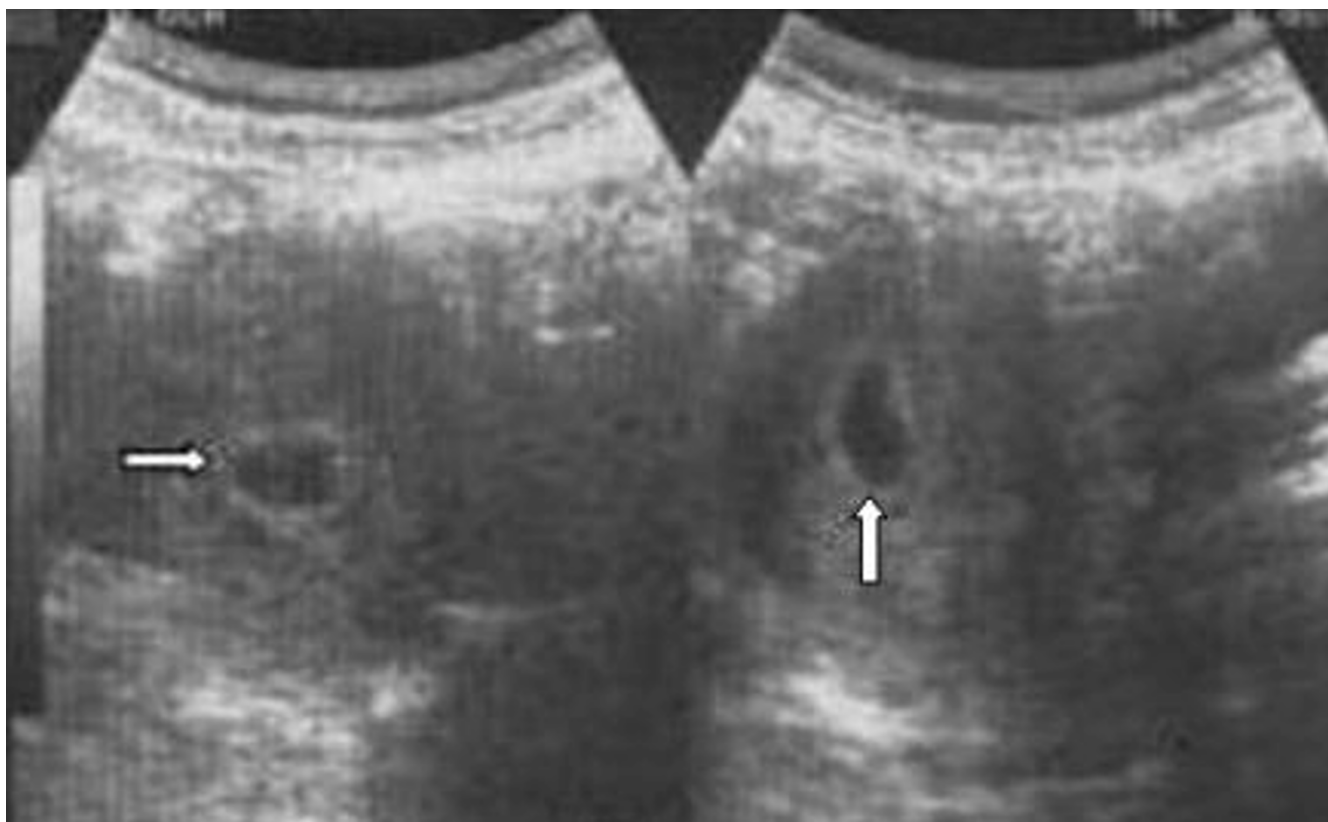

Figure 1

Ultrasonographic image of the case, monochorionic triamniotic triplet pregnancy, is demonstrating single chorionic cavity at 6 weeks of gestation (arrows).

Triplet pregnancies are at an increased risk for pregnancy complications and have higher perinatal morbidity and mortality rates, such as vascular anastomoses and developmental anomalies. In this report we present a case of monochorionic triamniotic triplet pregnancy with a co-triplet discordant for multicystic lung lesion, suggestive of congenital cystic adenomatoid malformation (CCAM).

Case presentation

A 26 year-old woman was referred to our maternal and fetal unit for detailed ultrasonographic examination because of triplet pregnancy with threatened abortion at 15 weeks of gestation. Her obstetric history included two first trimester abortions. The patient had taken no medication or drug for ovulation induction. An inquiry into the family history revealed that her mother had delivered triplet babies all of whom died in the early neonatal period. In the present case, the attending obstetrician had performed an ultrasonography at 6 weeks of gestation demonstrating a single, 17 × 20 mm gestational sac (chorion) (Figure 1).

Detailed ultrasonography at our maternal and fetal unit revealed a monochorionic triamniotic triplet pregnancy. Three thin amniotic membranes and an ipsilon zone were detected. The biometric measurements of the three distinct fetuses were appropriate for 15 weeks of gestation. The parents were informed about the risks of a multiple pregnancy and monochorionic placentation. After three days' hospitalization, the vaginal bleeding ceased and the patient was discharged to follow-up.

The obstetric course was unremarkable until 24 weeks, when ultrasonographic examination revealed that one of the triplet fetuses had developed a multicystic lung lesion suggestive of CCAM, with the largest cyst measuring 10 mm in diameter (Figure 2). Until 30 weeks of gestation, the fetuses had appropriate growth, and follow-up of the pregnancy was uneventful except that the fetus with CCAM developed mild polyhydramnios. At 30 weeks, the patient presented with preterm uterine contractions that ceased after tocolysis with nifedipine 60 mg per day. Betamethasone (12 mg × 2 doses in 24 hours) was

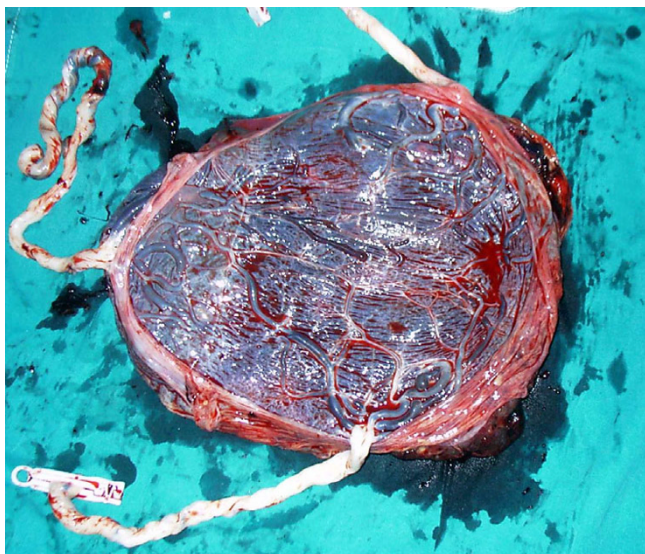


Figure 3
The photograph is demonstrating a single placenta with marginal cord insertion.

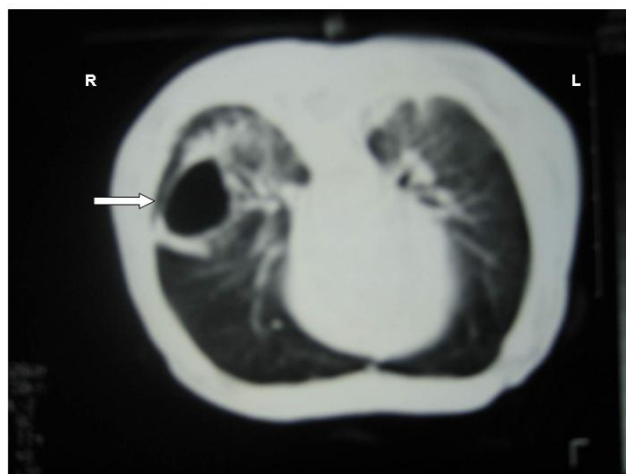


Figure 5
A repeat computerized tomography of the infant at 6 months presents a 30 mm solitary cystic mass (arrow).

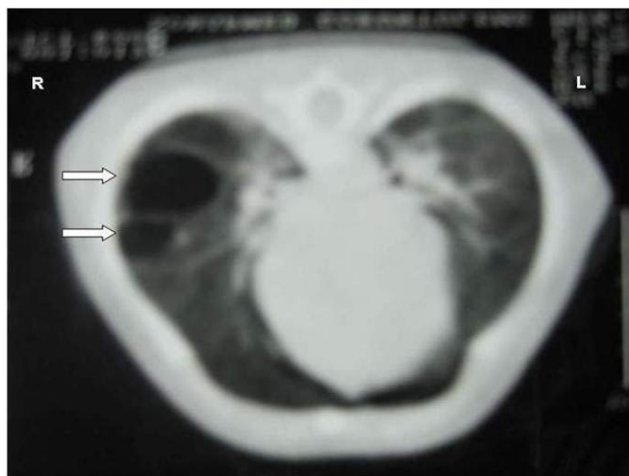


Figure 4
Computerized tomography of the infant at 3 months: two cystic masses in the middle lobe of the right lung, suggesting congenital cystic adenomatoid malformation (arrows).

Conclusion

The rate of monozygotic triplet pregnancies in a triplet population is estimated as 4.5%, but the fraction of monozygotic triplets remains unknown [5]. Splitting of the zygote at various stages of development leads to monozygotic multiple pregnancy. The mechanism of monozy-

gotic twinning is not clear. But it is well known that obstetric outcome and clinical management of multiple pregnancies depend on chorionicity. Chorionicity can be established in the first trimester with ultrasound by defining the number of gestational sacs or ipsilon zone [2]. In our case we determined monozygotic placentation by demonstrating a single gestational sac at 6 weeks and ipsilon zone at 15 weeks, and by pathological examination of the placenta after delivery.

The reported incidence of CCAM is approximately one in 10,000–25,000 pregnancies [6,7]. This abnormality is believed to be the result of hamartomatous change in the tertiary bronchioles or an arrest in the embryologic development between 7 and 15 weeks of gestation [8]. It is observed as cystic mass occupying part or the entire fetal lung, predominantly located in the right hemithorax, with up to 15% of cases having bilateral involvement. Prenatal prognostic features for CCAM include size, laterality, progression or regression of the mass, cardiac axis deviation, presentation with hydrops or polyhydramnios [6-8]. Partial or complete regression of the pulmonary lesion is possible. Conservative management is suggested in cases of fetal CCAM without significant mediastinal compression, hydrops fetalis or severe polyhydramnios [6].

Because of the rarity of monozygotic triplet pregnancies, there is no established guideline for management. The presence of an anomalous fetus further complicates the management of pregnancy. Feto-feto-fetal transfusion, acardiac fetus and conjoined twins in triplet gestations have been reported. However, to our knowledge, there are

no reports of prenatal diagnosis of a monochorionic triplet pregnancy with a co-triplet fetus discordant for CCAM of the lung.

In our case, a monochorionic triamniotic triplet pregnancy with a co-triplet fetus discordant for CCAM was managed conservatively until 35 weeks of gestation and three live fetuses were delivered. These findings may help in decision-making and counselling of parents.

Competing interests

The author(s) declare that they have no competing interests.

Authors' contributions

AG, HA and AC were the consulting perinatologists associated with the case. AG drafted the manuscript, HA participated in the design of the manuscript and AC participated in editing of the manuscript. YC was the director of the Maternal and Fetal Medicine Unit and participated in the design and revision of the manuscript. AIT was the director of the Reproductive Medicine Unit and participated in the design and revision of the manuscript.

References

1. Hecht BR: **The impact of assisted reproductive technology on the incidence of multiple gestations.** In *Multiple pregnancy. Epidemiology, Gestation and Perinatal Outcome* Edited by: Keith LG, Papiernik E, Keith DM, Luke B. London: The Parthenon Publishing Group; 1995:175-190.
2. Sepulveda W, Sebire NJ, Odibo A, Psarra A, Nicolaides KH: **Prenatal determination of chorionicity in triplet pregnancy by ultrasonographic examination of the epsilon zone.** *Obstet Gynecol* 1996, **88**:855-858.
3. Ulug U, Jozwiak EA, Mesut A, Bener F, Bahceci M: **Monochorionic triplets following intracytoplasmic sperm injection: A report of two consecutive cases.** *Gynecol Obstet Invest* 2004, **57**:177-180.
4. Ghulmiyyah LM, Perloe M, Tucker MJ, Zimmermann JH, Eller D, Sills ES: **Monochorionic-triamniotic triplet pregnancy after intracytoplasmic sperm injection, assisted hatching, and two-embryo transfer: first reported case following IVF.** *BMC Pregnancy and Childbirth* 2003, **3**:4.
5. De Catte L, Camus M, Foulon W: **Monochorionic high-order multiple pregnancies and multifetal pregnancy reduction.** *Obstet Gynecol* 2002, **100**:561-6.
6. Duncombe GJ, Dickinson JE, Kikiros CS: **Prenatal diagnosis and management of congenital cystic adenomatoid malformation of the lung.** *Am J Obstet Gynecol* 2002, **187**:950-4.
7. Laberge JM, Flageole H, Pugash D, Khalife S, Blaie S, Filiatraut D, Russo P, Lees G, Wilson RD: **Outcome of the prenatally diagnosed congenital cystic adenomatoid lung malformation: a Canadian experience.** *Fetal Diagn Ther* 2001, **16**:178-86.
8. Adzick NS, Harrison MR, Crombleholme TM, Flake AW, Howell LJ: **Fetal lung lesions: management and outcome.** *Am J Obstet Gynecol* 1998, **179**:884-9.

Publish with **BioMed Central** and every scientist can read your work free of charge

"BioMed Central will be the most significant development for disseminating the results of biomedical research in our lifetime."

Sir Paul Nurse, Cancer Research UK

Your research papers will be:

- available free of charge to the entire biomedical community
- peer reviewed and published immediately upon acceptance
- cited in PubMed and archived on PubMed Central
- yours — you keep the copyright

Submit your manuscript here:
http://www.biomedcentral.com/info/publishing_adv.asp

